

Inverted T Incision with Osteophyte Removal in The Treatment of Pincer Nail

by Anis Anwar

FILE	JURNAL_ERLIAN_2020.PDF (262.47K)	WORD COUNT	1742
TIME SUBMITTED	04-DEC-2020 11:01AM (UTC+0700)	CHARACTER COUNT	9155
SUBMISSION ID	1464257966		

Case Report

Authors:

Erlan Dimas Anggraini¹
Anis Irawan Anwar¹

¹ Department of Dermatology and Venereology, Faculty of Medicine, Universitas Hasanuddin

Correspondence:

Erlan Dimas Anggraini
Jl. Perintis Kemerdekaan KM 10, Tamalanrea Indah, Makassar, Indonesia 90245
erlian_dimasanggraini@yahoo.com

Received on: 19/12/2019

Approved on: 17/02/2020

Study conducted at the Dermatology and Venereology Department, Faculty of Medicine Hasanuddin University, Hasanuddin University Hospital, Makassar, South Sulawesi, Indonesia.

Financial support: None.

Conflict of interests: None.



Inverted T Incision with Osteophyte Removal in The Treatment of Pincer Nail

Incisão em T invertido com remoção de osteófitos, no tratamento da unha em pinça

DOI: <http://www.dx.doi.org/10.5935/scd1984-8773.20201211505>

ABSTRACT

Pincer nail deformity is characterized by excessive transverse over curvature of the nail. A 58-year-old woman came with a complaint of pincer nail accompanied by swelling and pain in the last 1 month due to frequent use of narrow shoes. We performed a surgical intervention indicated to treat pain, inflammation, interference with wearing shoes, and cosmetic embarrassment using an inverted T incision method with osteophyte removal. This case showed that the surgical approach did not require a long time to be conducted, presenting brief healing time, minimal pain, and excellent cosmetic outcome.

Keywords: Osteophyte; Ambulatory surgical procedures; Nails, malformed

RESUMO

A deformidade da unha em pinça é caracterizada por excessiva curvatura transversal da unha. Uma mulher de 58 anos apresentou-se com queixa de unha em pinça acompanhada de edema e dor no último 1 mês devido ao uso frequente de sapatos estreitos. Foi realizada uma cirurgia para tratar dor, inflamação, interferência no uso de calçados e cosmético, utilizando o método de incisão em T invertido com remoção de osteófitos. Este caso mostrou que a abordagem cirúrgica não foi demorada, apresentando curto tempo de cicatrização, dor mínima e excelente resultado cosmético.

Palavras-Chave: Osteófito; Procedimentos cirúrgicos ambulatoriais; Unhas mal formadas

INTRODUCTION

Pincer nail deformity is a nail disorder of the hands and feet characterized by an excessive transverse over the curvature of the nail, which is caused by osteophyte formation in the distal phalanx.³ Cornelius and Shelley first described pincer nail deformity⁷ in 1968 as a transverse distal over the curvature of the nail.² Based on its etiology, there are four distinct types of pincer nail: hereditary pincer nails, posttraumatic pincer nails, pincer nails⁴ arthropathic disorders, and pincer nail affecting a single nail.³ Foot alterations because of narrow shoes or osteoarthritis are reported to cause pincer nails.⁴ A pincer nail compresses the nail bed leading to p⁶ during walking or exercising as well as cosmetic problems.⁵ Pain may arise due to the embedding of the pincer nail in the lateral nail folds and nail bed, which becomes more pronounced distally.⁶ Several conservative and surgical treatment methods have been suggested to correct pincer nail deformities.⁷ However, there is still no established standard method for treating pincer nail deformity currently.⁷

Pincer nail is rarely found and reported in our region. Also, when a diagnosis is established, patients are⁹ ten reluctant to undergo surgical correction. Here, we report the first case of pincer nail deformity surgical correction with osteophyte removal in our center.

8
CASE REPORT

A 58-year-old woman presented to the Outpatient Department of Dermatology Hasanuddin University Hospital, Makassar, South Sulawesi, Indonesia, with a complaint of pincer-shaped right toenail accompanied by swelling and pain since one month before admission. Initially, the patient reported she had noticed the nail deformity since two years ago; however, at that time, there were no complaints, so the patient did not seek treatment.

There was a history of trauma to the right toenail due to the frequent use of narrow shoes. The patient had diabetes and routinely consumed metformin twice a day in the last five years. Also, the patient had a history of uncontrolled hypertension. The patient denied having a history of similar complaints before or in her family.

The patient was otherwise in good general condition. Dermatological examination showed nails clamping towards the medial and edema on the first finger of the right foot (Figure 1A). Considering the history and physical examination, we decided to perform corrective surgery using the inverted T incision method.

The surgery was conducted under local digital block anesthesia using 1% lidocaine after disinfection with povidone-iodine. A digital tourniquet application was applied to prevent

bleeding during the procedure. The first step was to perform a total nail avulsion by using iris scissors and nail splitters to separate the nails from the nail bed (Figure 1B). Precaution was taken not to injure the nail bed. In the second step, an inverted T incision, starting from the medial nail bed extending to the hyponychium down to the bone, was made using a sharp knife (blade #11) to explore the distal phalanx and expose the osteophyte (Figure 1C). In the third step, after the nail bed was cut along the previously determined incision line, osteophytes were found on the surface of the distal phalanx (Figure 1D) and were subsequently removed (Figure 1E). In the fourth step, the nail bed was sutured, and the medial nail bed (which was widened by the incision) was sutured using polyglactin 4-0 (Figure 1F). Both sides of the nail bed were sutured separately to the lateral borders (Figure 1G). This suture was maintained for three weeks to keep the nail bed stretched over the bone. A significant improvement on the nails was observed after 6 months.

DISCUSSION

The over curvature of the nails is commonly called pincer nails, tubed nails, or trumpet nails.⁸ The risk of pincer nails is higher in the big toenails compared to the fingernails, and its incidence rate is two times higher in women than in men.⁴ Pincer nail deformity should be diagnosed and treated because

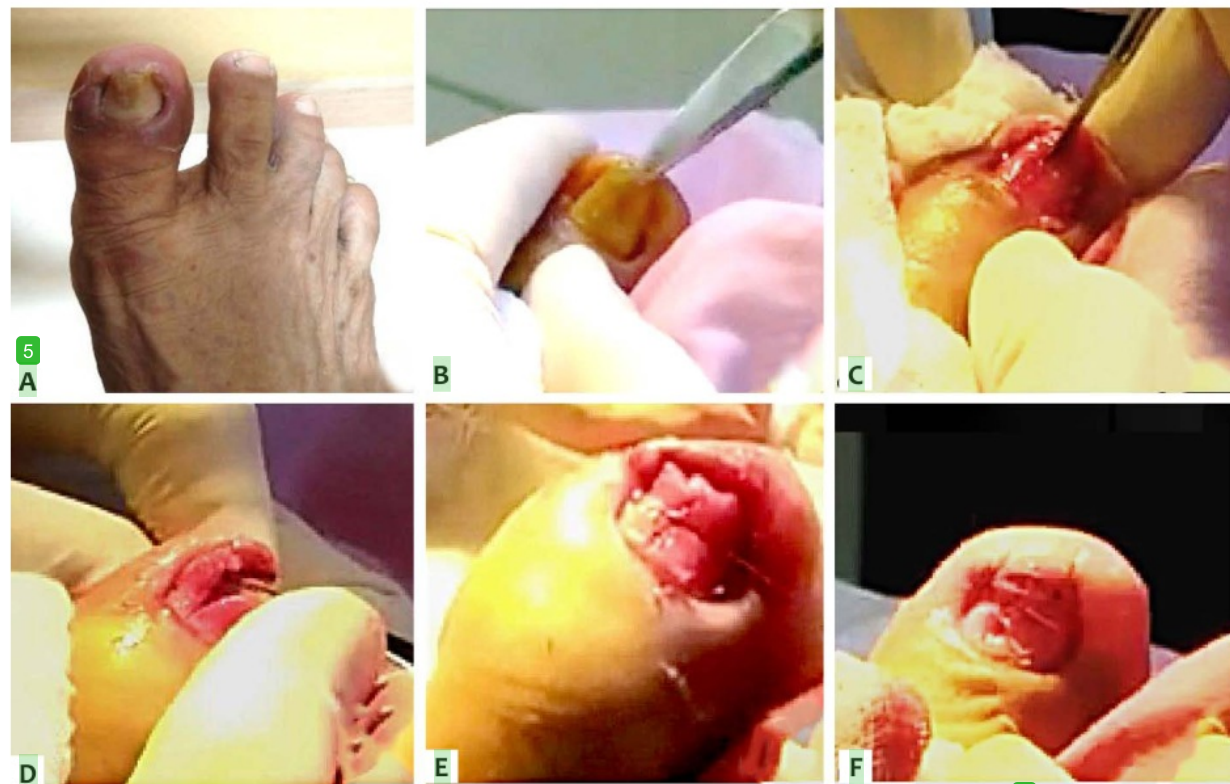


FIGURE 1: Pincer nail on the patient's right big toe (A). Total nail avulsion (B). Inverted T incision starting from the medial part of the medial nail plate and extending to the hyponychium (C). Exploration of the dorsal aspect of the distal phalanx (D). Removal of osteophytes in the dorsal phalanx (E). Suture in the medial part of the nail bed after removal of osteophytes (F). Suture on both sides of the nail bed at the lateral edges (G).

it affects not only the appearance but also the function of the digit and the quality of life due to the pain it causes.⁹ Cosmetic results of pincer nail surgery have become more critical because of the increasing demand for nail preservation and excellent aesthetic outcome.¹⁰ Surgical methods include nail avulsion, total or partial excision of the nail bed, phenol matrixectomy of the lateral matrix horns, destruction of the matrices by electrocauterization, removal of osteophytes, skin or mucosal grafting of the nail bed, zigzag nail bed flap method, and others.¹¹

As excessive osteophyte and narrow nail bed are the underlying factors of the pincer nail, removal of osteophyte and widening of the nail bed are expected to provide an ideal anatomical structure for the healthy growth of the future toenail.³ Inverted T incision is the method of choice that can be used in

high-risk groups, including elderly patients over 70 years old and those with diabetes mellitus, chronic kidney disease, and/or peripheral vascular disease because this method is less invasive than the zigzag nail bed flap method.²

CONCLUSION

Correction of pincer nail deformity using the inverted T incision approach is a simple and effective procedure because of shorter operating time, reduced pain during surgery, excellent functional and aesthetic outcome. ●

REFERENCES

- Altun S, Gürger M, Arpacı E, İnözü E. Correction of pincer nail deformity with dermal flap: a new technique in pincer nail deformity surgery. *Acta Orthop Traumatol Turc.* 2016;50(3):362-5.
- Jung DJ, Kim JH, Lee HY, Kim DC, Lee SI, Kim TY. Anatomical characteristics and surgical treatments of pincer nail deformity. *Arch Plast Surg.* 2015;42(2):207-13.
- Markeeva E, Hinterberger L, Vogt T, Rass K. Combined surgical treatment of a pincer nail with chemical matrixectomy, median nail incision, and splinting. *J Dtsch Dermatol Ges.* 2015;13(3):256-9.
- Noh SH, Na GH, Kim EJ, Park K. Significance of Surgery to Correct Anatomical Alterations in Pincer Nails. *Ann Dermatol.* 2019;31(1):59-65.
- Shin WJ, Chang BK, Shim JW, Park JS, Kwon HJ, Kim GL. Nail plate and bed reconstruction for pincer nail deformity. *Clin Orthop Surg.* 2018;10(3):385-8.
- de Berker DA, Richert B, Baran R. Acquired disorders of the nails and nail unit. In: Griffiths C, Barker J, Bleiker T, Chalmers R, Creamer D, editors. *Rook's Textbook of Dermatology.* New Jersey: Wiley-Blackwell; 2016. p.1-76.
- Cho YJ, Lee JH, Shin DJ, Sim WY. Correction of pincer nail deformities using a modified double Z-plasty. *Dermatol Surg.* 2015;41(6):736-40.
- Haneke E. Nail Disorders. In: Kang S, Amagai M, Bruckner AL, Enk AH, Margolis DJ, McMichael AJ, et al, editors. *Fitpatrick's Dermatology in General Medicine.* New York: Mc Graw Hill Education; 2019. p. 1568.
- Muslim MYBA, Chuah CK. Correction Of Pincer-Nail Deformity Using Autologous Full Thickness Skin Graft: A Case Report. *Malaysia Jour Dermatology.* 2017;39:79-81.
- Aksoy B, Aksoy HM. Novel surgical method for pincer nail treatment: Partial matrixectomy and triple flap technique. *Dermatol Surg.* 2017;43(11):1397-1399.
- Chang P, Argueta G. Pincer nail. *Our Dermatology Online.* 2016;7(2):234-237.

AUTHORS' CONTRIBUTIONS:

Erlan Dimas Anggraini |  ORCID 0000-0002-1889-6752

Approval of the final version of the manuscript; study design and planning; preparation and writing of the manuscript; data collection, analysis, and interpretation; intellectual participation in propaedeutic and/or therapeutic conduct of studied cases; critical literature review; critical revision of the manuscript.

Anis Irawan Anwar |  ORCID 0000-0002-1830-5617

Approval of the final version of the manuscript; preparation and writing of the manuscript; data collection, analysis, and interpretation; intellectual participation in propaedeutic and/or therapeutic conduct of studied cases; critical revision of the manuscript.

Inverted T Incision with Osteophyte Removal in The Treatment of Pincer Nail

ORIGINALITY REPORT

% **18**
SIMILARITY INDEX

% **6**
INTERNET SOURCES

% **17**
PUBLICATIONS

% **0**
STUDENT PAPERS

PRIMARY SOURCES

- 1** ALTUN, Serdar, GÜRGER, Murat, ARPACI, Enver and İNÖZÜ, Emre. "Correction of pincer nail deformity with dermal flap: a new technique in pincer nail deformity surgery", Türk Ortopedi ve Travmatoloji Derneği/Turkish Association of Orthopaedics and Traumatology, 2016.
Publication % **5**
- 2** www.odermatol.com
Internet Source % **3**
- 3** Dong Ju Jung, Jae Hee Kim, Hee Young Lee, Dong Chul Kim, Se Il Lee, Tae Yeon Kim. "Anatomical Characteristics and Surgical Treatments of Pincer Nail Deformity", Archives of Plastic Surgery, 2015
Publication % **3**
- 4** synapse.koreamed.org
Internet Source % **2**
- 5** Bertrand Richert, Nilton Di Chiacchio, Marie Caucanas, Nilton Gioia Di Chiacchio. % **2**

"Management of Ingrowing Nails", Springer

Nature, 2016

Publication

6

D. A. R. De Berker. "Disorders of Nails", Rook's Textbook of Dermatology, 01/01/2004

Publication

%2

7

Markeeva, Evgenia, Louisa Hinterberger, Thomas Vogt, and Knuth Rass. "Combined surgical treatment of a pincer nail with chemical matricectomy, median nail incision, and splinting : Dermatochirurgie - Tricks of the Trade/Dermatosurgery - Tricks of the Trade", JDDG Journal der Deutschen Dermatologischen Gesellschaft, 2015.

Publication

%1

8

Joshua E. Lane. "Avulsion and Partial Matricectomy with the Carbon Dioxide Laser for Pincer Nail Deformity", Dermatologic Surgery, 3/2004

Publication

%1

9

T H V Azevedo, C L S Neiva, R V Consoli, A C D Couto, A F M P Dias, E J R Souza. "Pincer nail in a lupus patient", Lupus, 2017

Publication

%1

EXCLUDE
BIBLIOGRAPHY

ON

WORDS